

May 2013

ELDER CARE

A Resource for Interprofessional Providers

Amyloid Imaging for Alzheimer's Disease

Phillip H. Kuo, MD, PhD, Department of Medical Imaging, University of Arizona
Geoffrey L. Ahern, MD, PhD, Department of Neurology, University of Arizona

In April 2011, the US Food and Drug Administration (FDA) approved florbetapir (trade name Amyvid), the first drug for the imaging of beta-amyloid plaque in the brain. Beta-amyloid plaques in the brain are the hallmark of Alzheimer's disease (AD). Previously, making a definitive diagnosis of Alzheimer's disease required post-mortem autopsy of the brain to evaluate for amyloid plaque using a special stain and a microscope. With florbetapir, the presence of amyloid plaque can now be detected non-invasively in live patients during a positron emission tomography/computed tomography (CT/PET) scan.

Florbetapir is labeled with radioactivity and when injected intravenously, the florbetapir binds to amyloid in the brain and the radioactive label allows localization. The radioactivity decreases by half every 2 hours. Given this rapid decay, no special radiation precautions are required. The typical PET/CT scan with florbetapir delivers approximately the same amount of radiation as 3 years of background radiation.

After florbetapir is injected, it is allowed to circulate for 30 minutes. The patient then lies down in a PET/CT scanner (Figure 1). A CT scan of the head is performed in a few seconds and is followed by a ten-minute PET scan. The radiologist then views the three-dimensional image of the brain as slices. Normal scans will show accumulation of radiolabelled florbetapir only in the white matter (Figure 2), while abnormal scans with significant amounts of amyloid plaque will show radioactivity in the white and gray matter out to the periphery of the brain (Figure 3). Although the popular press often displays images of florbetapir scans in color, in routine practice radiologists evaluate the scans in black-and-white.

Although approved by the FDA, florbetapir imaging for AD is not currently covered by Medicare. Most other health plans also do not provide coverage for the scans.

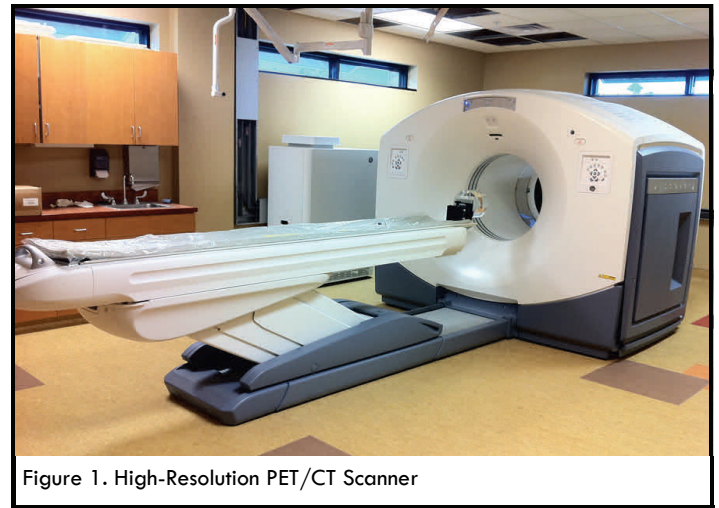


Figure 1. High-Resolution PET/CT Scanner

One reason for the lack of coverage is concern about the costs (about \$3,000 per scan) that will be generated by extensive use of this imaging to diagnose AD when no therapy is approved to slow or stop the disease after it has been diagnosed.

Concern has also been expressed that a positive florbetapir scan does not by itself provide a definitive diagnosis of AD. For example, some cognitively normal older adults will have a positive scan, even though they do not have and may never develop AD. Patients who have Lewy body dementia (LBD) may also have a positive scan when amyloid is present in the brain, even though AD is not the primary cause of the patient's dementia. In such cases, a dopamine transporter (DaT) scan can help sort out the basis for the patient's cognitive dysfunction.

Conversely, a negative scan means that a patient has little or no amyloid plaque at the time of the scan. But, it does not mean that the patient will never develop amyloid plaque in the future.

TIPS FOR USE OF AMYLOID IMAGING FOR DIAGNOSIS ALZHEIMER'S DISEASE

- Keep in mind that currently, Medicare and most health insurance plans will not pay for amyloid scans. So, only order them if they will change the plan of care.
- A patient with a typical presentation of Alzheimer's disease (AD) does not usually require amyloid imaging for confirmation of the diagnosis.
- Consider ordering an amyloid scan if it would be useful to identify the presence of amyloid, and thus confirm or exclude a diagnosis of AD in patients who present with Alzheimer's-like dementia at a younger-than-expected age, in patients with mild cognitive impairment who do not meet criteria for AD, and in those with an unclear diagnosis.

ELDER CARE

Continued from front page

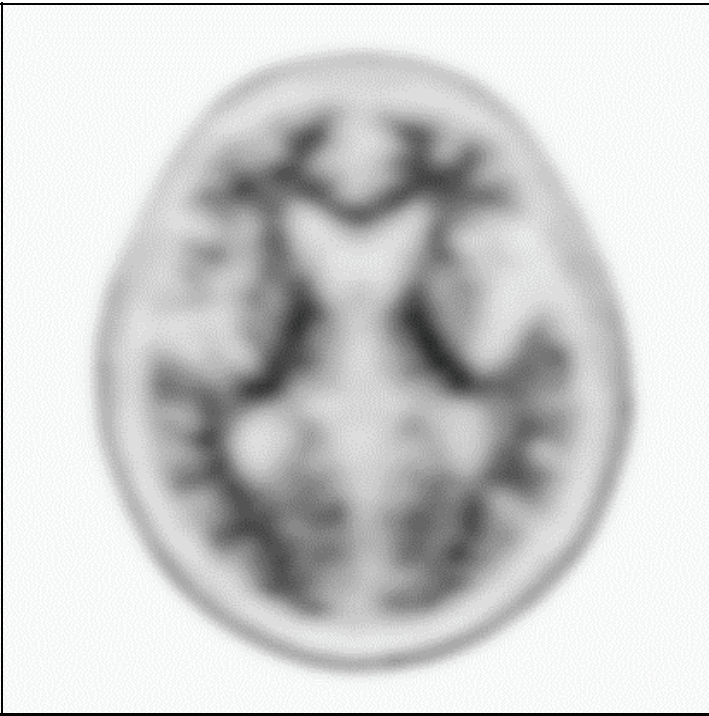


Figure 2. Negative Amyloid Scan. This PET/CT scan is negative for significant amyloid in the brain. The radiopharmaceutical (black) accumulates only in the white matter in a pattern that can be described as “mountain ridge”. This scan is not consistent with Alzheimer’s disease.

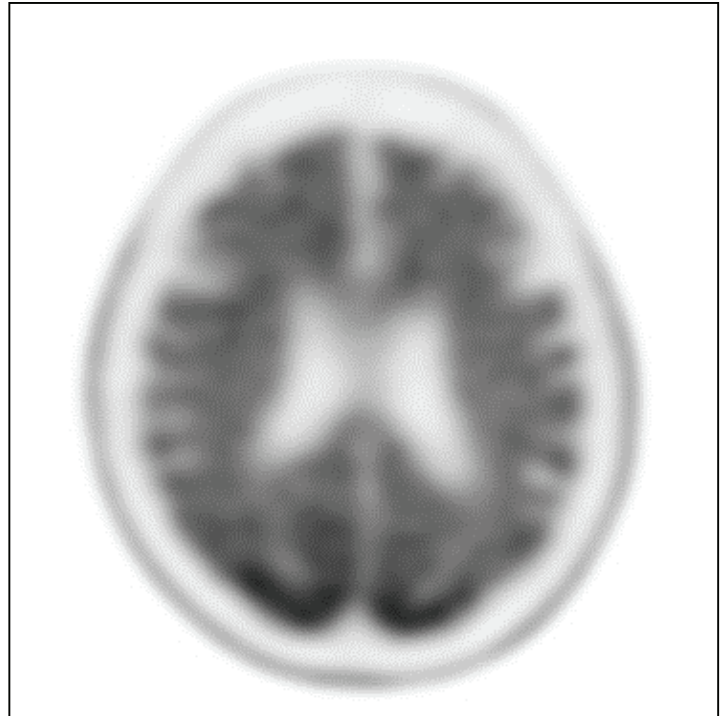


Figure 3. Positive Amyloid Scan. This PET/CT scan is positive for significant amyloid in the brain. The radiopharmaceutical (black) accumulates in both the white and gray matter, with distribution out to the periphery of the brain. This scan is consistent with Alzheimer’s disease.

Still, there are several clinical situations in which florbetapir scans have potential utility. One is when a patient exhibits findings of AD at a younger-than-expected age (such as a patient with a presenilin-1 mutation). A second is to determine if a patient with mild cognitive impairment who does not meet criteria for AD is simply demonstrating normal age-related memory changes or if the patient is in the early stages of AD. The third is when a patient’s presentation has a differential diagnosis that includes conditions such as frontotemporal dementia, primary progressive aphasia, or posterior cortical atrophy/visual-variant Alzheimer’s syndrome, and the correct diagnosis is unclear. In all of these situations,

the presence of significant amyloid on PET/CT would suggest that amyloid pathology is causing the patient’s cognitive impairment, regardless of the clinical presentation.

The other potential use of florbetapir scans is for research on new AD treatments. To determine the efficacy of such treatments, it will be essential to confirm that research subjects do, in fact, have AD. Detection of amyloid with a florbetapir scan will provide that confirmation. Similarly, when studying therapies designed to target amyloid plaque with the intention of slowing the progression of AD, serial florbetapir scans will permit longitudinal assessment of therapeutic outcome.

References and Resources

- Clark CM, Schneider JA, Bedell BJ, et al. Use of florbetapir-PET for imaging beta-amyloid pathology. *JAMA*. 2011; 205:275-283.
- Johnson KA, Sperling RA, Gidyczon CM, et al. Florbetapir (F18-AV-45) PET to assess amyloid burden in Alzheimer’s disease dementia, mild cognitive impairment, and normal aging. *Alzheimers Dement*. 2013; Published online Feb 1, 2013.
- Mitka M. PET imaging for Alzheimer Disease: Are its benefits worth the cost? *JAMA*. 2013; 309:1099-1100.
- Wenger, NS, et al. Introduction to the assessing care of vulnerable elders-3 quality indicator measurement set. *Journal of the American Geriatrics Society*, 2007. 55: p. S247-S252.
- Yang L, Rieves D, Garley C. Brain amyloid imaging—FDA approval of florbetapir F18 injection. *N Eng J Med*. 2012; 387:885-887.

ACOVE Quality Indicators

IF a vulnerable elder is admitted to a hospital or is new to a physician practice, THEN multidimensional assessment of cognitive ability and assessment of functional status should be documented.

Interprofessional care improves the outcomes of older adults with complex health problems

Editors: Rosemary Browne, MD; Mindy Fain, MD; and Barry D. Weiss, MD

Interprofessional Associate Editors: Tracy Carroll, PT, CHT, MPH; Karen D’Huyvetter, ND, MS; Carol Howe, MD, MLS; Colleen Keller, PhD, FNP; Teri Kennedy, PhD, LCSW, MSW; Jeannie Lee, PharmD, BCPS; Jane Mohler, NP, MPH, PhD; Lisa O’Neill, MPH
The University of Arizona, PO Box 245069, Tucson, AZ 85724-5069 | (520) 626-5800 | <http://aging.medicine.arizona.edu>

Supported by: Donald W. Reynolds Foundation, Arizona Geriatric Education Center and Arizona Center on Aging